

Evaluation of the Therapeutic Effect of Lycopene on Cypermethrin-Induced Reproductive Toxicity in Rats

Adetutu Olubunmi Obulor¹ and Eme Efioanwan Orlu²

Department Of Animal and Environmental Biology

Rivers State University, P.M.B 5080, Nkpolu-Oroworukwo, Rivers State Port Harcourt, Nigeria

Corresponding Author: Adetutu Olubunmiobulor

Abstract: *Cypermethrin is a type II synthetic pyrethroid prescribed for bed nets for neonates, infants and adults. This study aimed at evaluating its reproductive toxicity and therapeutic effect of co-administration of Lycopene on male rats. Histopathological evaluation of the testes revealed approximately 40% loss of germ cells including interstitial cells of Leydig and Sertoli cells. Luminal diameter increased with complete loss of spermatozoa indicating the inhibition of maturation and differentiation of secondary spermatocytes into mature spermatozoa. The seminiferous epithelium became sparsely populated due to mitotic inhibition. Animals co-administered Lycopene recovered as observed by the regeneration of all spermatogenic elements. It is concluded that processed *Solanum lycopersicum* and its pure extract exhibited a therapeutic effect on Cypermethrin-induced reproductive toxicity. It is also worthy of note that fresh fruits of *Solanum lycopersicum* possess some form of lycopene but require further processing to make it bioavailable to mammals lacking Cellulase.*

Key Words: *Cypermethrin, lycopene, spermatogenesis, antioxidant, reproductive stress*

Date of Submission: 17-03-2018

Date of acceptance: 02-04-2018

I. Introduction

Pesticides are the most effective means of pest eradication all over the world but they produce a number of adverse effects on non-target organisms [1,2]. Although regulatory agencies still consider registered pesticides an essential pest management tool with benefits outweighing health and environmental risk, research has shown that no pesticide especially insecticides is without adverse side effect [3,4,5,6]. Man and animals are inadvertently exposed not only to a cocktail of synthetic pyrethroids but also to other forms of Endocrine disrupting chemicals. These chemicals common in Cigarette smoke, radiation, pesticides, Industrial solvents and more induce oxidative stress which plays a vital role in the pathology of many degenerative diseases, as well as, reproduction in males and females [7,8]. Majority of the pesticides in use, Cypermethrin [9,10,11], Deltamethrin [5,12], Permethrin [13], allethrin [14] have resulted in decreased enzymatic antioxidant levels, hepatotoxic effects [15] increased sex cell abnormalities, birth defects, chromosomal aberrations, micronuclei formation and reproductive dysfunction.

Cypermethrin, a synthetic pyrethroid is one of the most commonly used insecticides in Agriculture, public, private and animal health programmes. Although considered safe and of low mammalian toxicity, reports have shown that Cypermethrin can induce adverse effects and reproductive dysfunction in males with indicators such as, abnormal sperm cell morphology, decrease in testicular testosterone production, reduction of sperm production, decrease in fecundity and more [4,5,6]. Although the reproductive system seems to be the main target of Pyrethroid pesticides, mammals have several mechanisms to counteract the deleterious effect by producing natural antioxidants, or externally through foods and/or supplements. Lycopene is a potent singlet oxygen scavenger whose antioxidant activity alleviates oxidative stress by reacting with free radicals [15, 16, 17,18]. Based on the increase in the use of Cypermethrin for neonates, infants and adult males and pregnant women for the purpose of control of mosquitoes in the Niger Delta region of South-South Nigeria, this study aimed at evaluating the potential protective effect of co-administration of Lycopene on reproductive toxicity induced by exposure to Cypermethrin.

II. Materials And Methods

2.1 Experimental Location

The study was carried out in the Reproductive Physiology and Genetics Research Laboratory of the Department of Applied and Environmental Biology, Rivers State University, Port Harcourt Oroworukwo, Rivers State. (Coordinates 4°47'50"N 6°58'49"E)

2.2 Experimental animals and Management

Twenty-eight sexually matured male Sprague-Dawley rats with mean weight of 236 ± 35.6 g were bred at the Reproductive Physiology and Genetics Animal House from parents obtained from the Department of Biochemistry, University of Port Harcourt, Nigeria. The rats were housed individually in plastic cages under standard conditions (12 hL:12hD,) and acclimated for two weeks prior to the commencement of the experiment. All animals were fed standard rodent pellet and cool clean water *ad libitum*. All experiments were conducted according to the institutional animal care protocols at the Rivers State University, Port Harcourt, Nigeria and followed approved guidelines for the ethical treatment of experimental animals.

2.3 Experimental Design and Procedure

The twenty eight adult male Sprague-Dawley rats were assigned to seven groups (A-G) made up of four rats each. Group (A) received neither Cypermethrin nor lycopene and served as control, Group B received Cypermethrin Emulsifiable Concentrate (EC) diluted to 30 mg/kg/bw/day with canola oil only, Group C and D were administered 5,000 and 10,000 mg/kg/bw/day of processed *Solanum lycopersicum* dissolved in distilled water as well as 30mg/kg/bw/day of Cypermethrin. Group (E and F) were co-administered 5,000 and 10,000mg/kg/bw/day of fresh *Solanum lycopersicum* and 30mg/kg/bw/day of Cypermethrin. Group G received 10mg/kg/bw/day of pure Lycopene dissolved in Canola oil with Cypermethrin at 30mg/kg/bw/day. All treatments were administered by oral gavage for 70 days. All animals were observed daily for behavioral changes; signs of intoxication, mortality, morbidity, food and water intake and were weighed with Denver Instrument Model BH210 twice a week and the average weight per week recorded to the nearest 0.01 g.

2.4 Potential systemic toxicity

The final bodyweight of the animals were recorded to the nearest 0.01 grams. The change in weight was obtained by deducting the initial bodyweight from the final weight.

At the end of the experiment the animals were euthanized by ethyl ether inhalation. Data were collected for the assessment of the following:

2.5 Effect on Gonadosomatic Indices

Experimental animals were dissected and the reproductive organs; prostate, testes, epididymides and seminal vesicles removed intact and freed from adhering tissues and weighed [5]. The weight were recorded and the gonadosomatic indices calculated as follows:

$$\text{Gonadosomatic index} = \frac{\text{Weight of reproductive Organs} \times 100}{\text{Body Weight}}$$

2.6 Histopathological analysis of the testis

Immediately after dissection, the testis was fixed in 10% v/v buffered formaldehyde and dehydrated through ascending grades of ethanol (70, 90, 95% v/v), cleared in xylene and impregnated and embedded in paraffin wax, from which sections $7 \mu\text{m}$ were cut with digital microtome (AO Spencer No.820). The sections were floated out on clean microscope slides, which had previously been albuminized to prevent detachment from slides during staining procedure. The slides were air-dried for 2hrs at 37°C , stained with haematoxylin and counter stained with eosin [19,20]. The slides were passed through ascending concentration of alcohol (20-100%) for dehydration and cleared with xylene, then mounted on basalm. The slides were viewed with a Trinocular microscope (Muller Germany R, Biosphere- B 2005T). Fifty random tubules were observed at X10 and X40 magnification and images recorded with a digital camera.

2.7 Statistical Analyses

Data obtained from the study were subjected to one-way ANOVA and means and standard deviations calculated with SPSS version 20. where significant differences were found, Pair-wise mean comparisons were conducted with Tukey test to evaluate the effect of Sub-chronic co-administration of Cypermethrin and Lycopene on the experimental animals.

III. Results

3.1 Potential Systemic toxicity

The results on the bodyweight and reproductive organ weights of experimental animals co-administered Cypermethrin and Lycopene is shown in Table 1. Animals in group B exposed to Cypermethrin only had bodyweights, significantly ($p < 0.05$) lower than the control, while group C, D, E, F and G had higher weights statistically non-significant ($p > 0.05$) when compared with the control group. Similar trends were observed in the paired testes weight ranging from 2.51 ± 0.09 g in the control group to 2.54 ± 0.52 g and 2.35 ± 0.02 g in the groups administered processed *Solanum lycopersicum* at 5,000 and 10,000mg/kg/bw/day respectively.

Groups E and F administered fresh *Solanum lycopersicum* showed lower but non-significant difference in paired testicular weight compared to the control. The lowest testicular weight (1.99±0.16g) and seminal vesicle was observed in the animals administered Cypermethrin only, and the differences were significant at (p<0.05) between the control and the exposed animals (see Table 1).

Table 1: Effect of co-administration of Cypermethrin Reproductive organ weights in rats

| GRPS | PROSTATE | RTW | LTW | PTW | REW | LEW | PEW | SEM. V. |
|---------|------------|------------|-------------|-------------|------------|------------|------------|------------|
| A | 0.54±0.02* | 1.24±0.09* | 1.27±0.11* | 2.51±0.19* | 0.75±0.07* | 0.76±0.0* | 1.51±1.13* | 1.31±0.07* |
| B | 0.24±0.27* | 0.86±0.22* | 1.12±0.10** | 1.99±0.16** | 0.48±0.14* | 0.54±0.1* | 1.02±0.26* | 0.58±0.09* |
| C | 0.49±0.01* | 1.12±0.01* | 1.22±0.01** | 2.35±0.02* | 0.64±0.05* | 0.68±0.0* | 1.32±0.09* | 0.96±0.19* |
| D | 0.51±0.07* | 1.25±0.26* | 1.29±0.26** | 2.54±0.52* | 0.64±0.09* | 0.74±0.0** | 1.38±0.14* | 1.00±0.2* |
| E | 0.34±0.22* | 0.93±0.22* | 1.11±0.03** | 2.04±0.19* | 0.43±0.22* | 0.65±0.12* | 1.08±0.34* | 0.82±0.02* |
| F | 0.39±0.09* | 1.23±0.13* | 1.24±0.13** | 2.48±0.26* | 0.54±0.11* | 0.69±0.15* | 1.23±0.25* | 0.78±0.41* |
| G | 0.52±0.09* | 1.3±0.02* | 1.38±0.01* | 2.68±0.02* | 0.67±0.08* | 0.76±0.05* | 1.43±0.13* | 1.02±0.19* |
| F-VALUE | 8.93 | 3.44 | 3.50 | 1.88 | 7.63 | 5.69 | 1.61 | 1.89 |
| SIG. | 0.00 | 0.03 | 0.03 | 0.15 | 0.01 | 0.04 | 0.22 | 0.15 |

RTW(right testis weight), LTW(left testis weight), PTW(paired testis weight), REW(right epididymal weight), LEW(left epididymal weight), PEW(paired epididymal weight), SEM.V(seminal vesicle).

3.2 Gonadosomatic indices

The effect of co-administration of Cypermethrin with Lycopene on the Gonadosomatic indices in Sprague-Dawley rats is shown in Table 2. There was no significant difference between the bodyweight of animals in the control group, and those co-administered CYP and processed and fresh *Solanum lycopersicum*, as well as, pure Lycopene. The bodyweight of rats administered Cypermethrin only was numerically lower than those that received the antioxidant in addition. The ratios of reproductive organs to bodyweight following euthanasia of the experimental animals ranged from 0.22±0.05 in the control, to 0.22±0.02 vs 0.24±0.04 in the group co-administered processed *Solanum lycopersicum* at both 5000 and 10,000mg/kg/bw/day. The paired testes to bodyweight ratio, paired epididymal and seminal vesicular weights did not differ significantly from those of the control animals neither were they significantly different from those administered fresh *S. lycopersicum* and pure Lycopene.

Table 2: Effect of Co-administration of Cypermethrin and Lycopene on the Gonadosomatic indices in Sprague-Dawley rats

| GRPS | GONADOSOMATIC INDICES (%) | | | | | | | | |
|-------|---------------------------|-----------|-----------|-----------|-----------|-----------|-----------|-----------|-----------|
| | BW | PROS | RTW | LTW | PTW | REW | LEW | PEW | SEM. V |
| A | 252.09±41.98 | 0.22±0.05 | 0.51±0.13 | 0.52±0.14 | 1.03±0.27 | 0.30±0.03 | 0.31±0.03 | 0.61±0.06 | 0.53±0.08 |
| B | 200.82±46.29 | 0.11±0.09 | 0.37±0.09 | 0.44±0.06 | 0.81±0.13 | 0.17±0.09 | 0.26±0.06 | 0.43±0.16 | 0.29±0.15 |
| C | 221.75±19.63 | 0.22±0.02 | 0.51±0.05 | 0.55±0.05 | 1.06±0.09 | 0.29±0.05 | 0.31±0.04 | 0.60±0.09 | 0.44±0.13 |
| D | 216.99±29.58 | 0.24±0.04 | 0.58±0.09 | 0.59±0.10 | 1.17±0.19 | 0.29±0.06 | 0.35±0.08 | 0.65±0.13 | 0.47±0.14 |
| E | 255.04±40.60 | 0.14±0.09 | 0.44±0.16 | 0.48±0.06 | 0.95±0.11 | 0.21±0.04 | 0.26±0.05 | 0.47±0.09 | 0.31±0.11 |
| F | 261.49±21.91 | 0.15±0.02 | 0.47±0.05 | 0.57±0.09 | 1.02±0.21 | 0.25±0.09 | 0.28±0.08 | 0.52±0.18 | 0.32±0.04 |
| G | 249.37±46.08 | 0.21±0.05 | 0.53±0.09 | 0.57±0.09 | 1.09±0.18 | 0.27±0.04 | 0.31±0.10 | 0.59±0.14 | 0.42±0.09 |
| F-VAL | 1.21 | 2.11 | 1.31 | 1.09 | 1.24 | 1.69 | 0.68 | 1.14 | 1.99 |
| SIG. | 0.36 | 0.12 | 0.31 | 0.42 | 0.35 | 0.19 | 0.67 | 0.39 | 0.14 |

*Values are Mean± SD .*BW(bodyweight), PROS(prostate), RTW(right testis weight), LTW(left testis weight), PTW(paired testis weight), REW(right epididymal weight), LEW(left epididymal weight),PEW(paired epididymal weight), SEM.V(seminal vesicle).

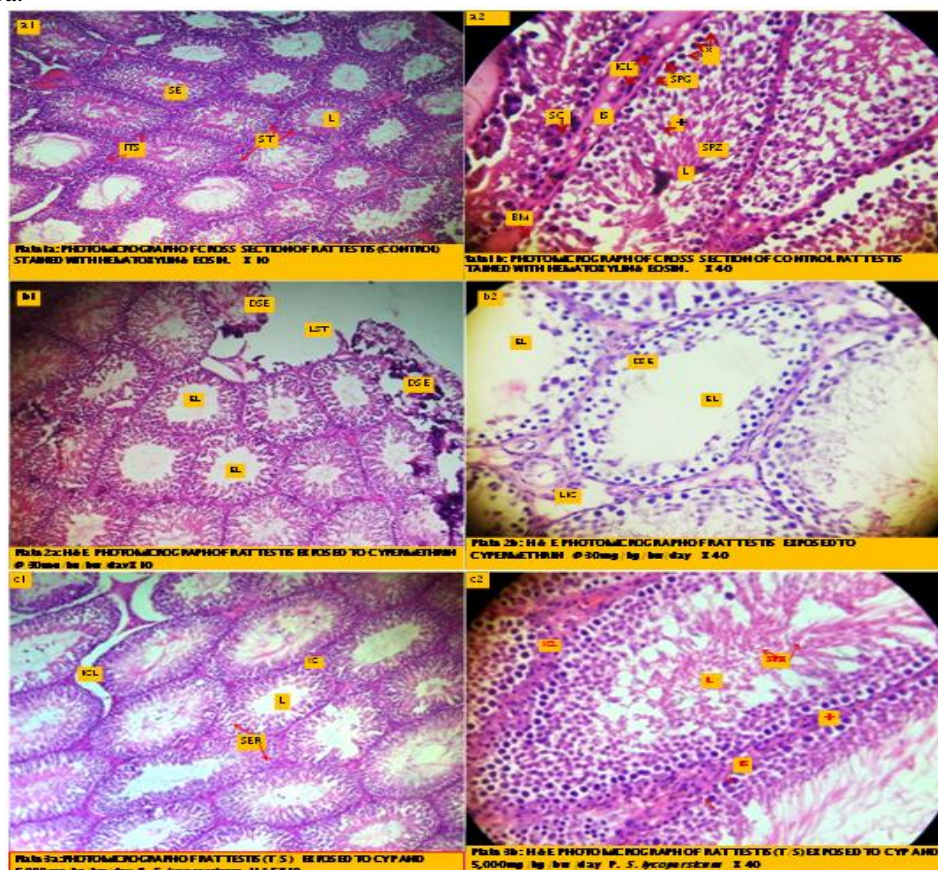
3.3 Histopathological evaluation of the testis

The evaluation of the testis of the experimental animals processed according to Hematoxylin and eosin (H&E) protocol and observed magnification X10 and 40 showed a normal seminiferous epithelium with seminiferous tubules showing full complements of spermatogenic elements(Fig1.a1 &a2), interstitial cells of Leydig located in the intertubular space (ITS),the lumen (L) filled with mature spermatozoa (spz) awaiting spermiation. Normal aggregation of the primary and secondary spermatocytes around the Sertoli cells(SC).The seminiferous epithelium maintained its integrity and remained attached to the basement membrane.

Micrographs b1 and b2are testicular cross sections of experimental animals exposed to 30mg/kg/bw/day of Cypermethrin only. Observation of 50 random seminiferous tubules at x 40 magnification revealed seminiferous epithelium degeneration (DSE) and approximately 40% loss of tubules.The luminal spaces increased in diameter and were completely devoid of spermatozoa(EL). There was drastic reduction in the number of interstitial cells of Leydig as well as Sertoli cells. Very few mitotic spermatogonia were observed at the basal compartment while the adluminal compartment showed sparse and scattered primary and secondary spermatocytes (see Fig.1b1 & b2).

The micrographs of rats exposed to 5,000 and 10,000mg/kg/bw/day are shown in Fig.1c1,c2,and d1,d2), there was reduction in the seminiferous tubule degeneration with only 15.55% tubular loss and epithelial degeneration observed. Interstitial cells of Leydig (ICL) were observed to have repopulated the interstitial space(IS). The basal compartment became lined with regenerated spermatogonia(RSE) Pre-meiotic spermatocytes were seen lining up between the basal and adluminal compartments with primary and secondary spermatocytes were in the adluminal compartment.

In Fig.1:e1,e2& f1,f2,the animals were exposed to CYP with 5,000 and 10,000mg/kg/bw/day of fresh *S.lycopersicum*. These seminiferous epithelium still exhibited mild signs of reproductive stress, including 25%degeneration and detachment from the basement membrane. Interstitial cells of Leydig were still not fully regenerated.(see arrow f2) . Group G animals were exposed to CYP and pure lycopene at 10mg/kg/bw/day, the testicular cross section is shown in Fig,1g1 & g2.The seminiferous epithelium appears to have fully recovered with normal complements of Leydig cells, mitotic and meiotic spermatogenic elements, mature and elongating spermatozoa.



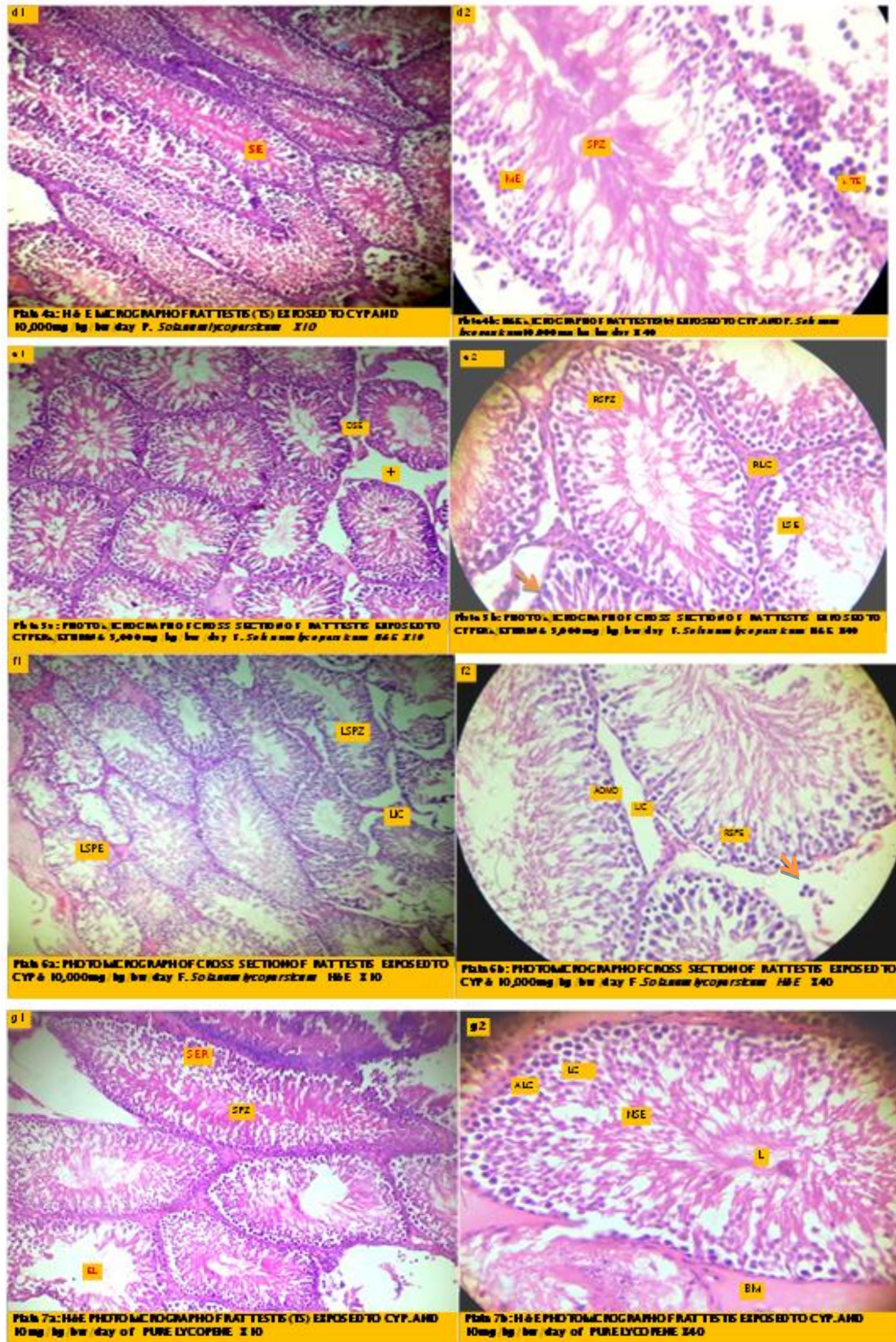


Fig.1a-g: Histopathological Micrographs of the Testes of Sprague-Dawley rats Co-administered Cypermethrin and Lycopene.

IV. Discussion

4.1.Changes in the body weight and relative weights are important criteria for evaluation of organ toxicity and can be used as a valuable tool or index of pesticides related organ damage [5]. In this study there was 25% loss in the bodyweight of animals exposed to Cypermethrin only, statistically ($p<0.05$) significantly different from the control. Those exposed to Cypermethrin and *Solanumlycopersicum* processed, fresh or purified Lycopene showed numerical but non-significant loss of bodyweight. This observation is indicative of systemic toxicityof Cypermethrin at 30mg/kg/bw/day in a sub chronic exposure.Cypermethrin is a type II synthetic pyrethroid commonly used for residential pest control, public and private health purposes. It is an active ingredient in the treatment of mosquito bed nets in West Africa to prevent malaria. Indoor and outdoor sprays such as Raid, Baygon, Rambo, Mortienare readily available in stores and supermarkets. Evaluation of the reproductive toxicity of Cypermethrin in testicular cross sections of experimental animals exposed to Cypermethrin only, revealed toxicity biomarkers such as seminiferous epithelium degeneration and approximately 40% loss of germ cells including interstitial cells of Leydig that is responsible for the production of androgens such as Testosterone and drastic reduction the Sertoli cell number. Similarly,there was 21% loss in paired testes weight, about 25 % loss in paired epididymal weight and 55% loss in Seminal vesicles (see Table2).This is in line with [5,20]who reported that reproductive organ weights are positively correlated with bodyweight. A critical observation of Fig.1b reveals increase in the diameterof the lumen and complete loss of luminal spermatozoa a strong indication of the inhibition of maturation and differentiation of secondary spermatocytes into mature spermatozoa. The sparselypopulated seminiferous epithelium is due to reduction in the number of spermatogonia undergoing mitotic cell division which controls approximately the number of spermatocytes committed to meiosisence the number spermatozoa produced per spermatogonium. The reduction in the number of germ cells can be attributed to the loss of interstitial cells of Leydig and Sertoli germ cell carrying capacity. Thus Cypermethrin exhibits classic Endocrine disrupting effect in the male rat studied. The function of androgens produced by Leydig cells and Sertoli cells include initiation and sustenance of spermatogenesis and spermiogenesis.Cypermethrin has the capacity to cross the blood-testis barrier formed by the Sertoli cells to render the adluminal compartment of the seminiferous tubule inaccessible to toxicants.Increase in the testicular and epididymal weights in the animals co-administered processed *Solanum lycopersicum* and pure lycopene is indicative of the therapeutic effect of Lycopene and its derivatives on Cypermethrin-induced reproductive toxicity (see Fig.1c,de,f,g).

V. Conclusion

Based on the recovery of the seminiferous epithelium as observed by the regeneration of the interstitial cells of Leydig,mitotic and meiotic germ cells, as well as, differentiation and maturation into spermatozoa of primary and secondary spermatocytes,it is hereby concluded that processed *Solanum lycopersicum* and its pure extract exhibited a therapeutic effect on Cypermethrin –induced reproductive toxicity in the experimental animal.It is also worthy of note that fresh fruits of *Solanum lycopersicum* possesses some form of lycopene but require further processing to make bioavailable to mammals lacking Cellulase enzyme.

References

- [1]. Bhushan, B., Pande, S., Saxena, N and Saxena., P.N. (2013). Serum biochemical responses under stress of Cypermethrin in albino rat.Environmental and Experimental Biology, 11, 81-89.
- [2]. Li, Y.F., J., Hajikhani, R. and Zaeim, R.T. (2010). Effects of Cypermethrin on sexual behaviour and plasma concentration of pituitary- gonadl hormones.International Journal of fertility and sterility, 4 (1), 23-28.
- [3]. Giray, B., Gürbay, A., Hincal, F. (2001). Cypermethrin-induced oxidative stress in rat brain and liver is prevented by Vitamin E or allopurinol. Toxicology Letters. 118(3). 139-46.
- [4]. Kjeldsen, L.S., Ghisari, M. and Bonefeld-Jorgensen, E.C. (2013). Currently used Pesticides and their mixtures affect the function of sex hormone receptors and aromatase enzyme activity. Toxicology and Applied Pharmacology, 453-464.
- [5]. Orlu, E.E. (2014). Deltamethrin-induced Alterations in Sperm Morphology and Spermatogenesis Impairment in Adult Sprague-Dawley Rats.Research Journal of Applied Sciences, Engineering and Technology, 7, (11), 2324-2331.
- [6]. Sharma, P., Huq, A.U. andSingh, R. (2014). Cypermethrin-induced reproductive toxicity in the rat is prevented by resveratrol. Journal of Human Reproductive Sciences, 7, (2), 99-106.
- [7]. Williams, M.K., Rundle, A., Holmes, D., Reyes, M., Hopner, L.A. and Barr, D.B. (2008). Changes in pest infestation levels, self-reported pesticide use, and permethrin exposure during pregnancy after the 2000-2001 U.S. Environmental Protection Agency restriction of organophosphates.Environmental Health Perspectives, 116, (12), 1681-8.
- [8]. Nasr, S., El-Moneim, A. A., Moghazy, A. andBadawi, M.M.(2015). Evaluation of an Antioxidant containing Drug Action against Pyrethroid Toxicity.Current Science International, 4,(3), 455-466.
- [9]. Poongothai, S., Ravikrishnan, R. and Murthy, P.B. (2007). Endocrine Disruption and Perspective Human Health Implications: A Review. The Internet Journal of Toxicology, 4 (2), 3-6.
- [10]. Abarikwu, S.O., Akiri, O.F., Durojaye, M.A. and Adenike, A.(2015). Combined effects of repeated administration of Bretmont wipeout (glyphosate) and ultrazin(atrazine) on testosterone, oxidative stress and sperm quality of wistar rats. Toxicology Mechanism and Methods, 25(1), 70-80.

- [11]. Sharma A, Sharma P, Sharma P and Joshi SC:(2015). A Review on Organochlorine Pesticides and Reproductive Toxicity in Males. *Int J Pharm Sci Res.* 6(8): 3123-38.
- [12]. Sengupta, P., and Banerjee, R. (2014). Environmental toxins: alarming impacts of pesticides on male infertility. *Human Experimental Toxicology*, 33, (10), 1017-39.
- [13]. Kim, S.S., Lee, R.D., Lim, K.J. (2005). Potential estrogenic and antiandrogenic effects of permethrin in rats. *J. Reprod.Dev.* 51, 201-10
- [14]. Madhubabu G &Yenugu. S. (2017). Allethrin toxicity causes reproductive dysfunction in male rats. *Environ. Toxicol.* 32(6), 1701-1710
- [15]. Elbetieha A, Daas SI, Khamas W, Darmani H (2001). Evaluation of the toxic potentials of Cypermethrin pesticide on some reproductive and fertility parameters in the male rats. *Arch. Environ. Contam.Toxicol.* 41: 522-528.
- [16]. Obulor-Godwin,A.O and Orlu. E.E. (2018).Inhibitory Activity of Lycopene on Cypermethrin-Induced Hepatotoxicity and Liver injury in male Sprague-Dawley Rats *IOSR Journal of Pharmacy and Biological Sciences*, 13(1), 63-73
- [17]. Sharma, P., Huq A, U. and Singh, R. (2013). Cypermethrin- induced reproductive toxicity in male Wistar Rat: Protective role of *Tribulusterrestris*. *Journal of Environmental Biology*, 34 ,857-862.
- [18]. Durairajanayagam D, Agarwal A, Ong C, Prashast P. (2014). Lycopene and male infertility. *Asian J Androl.* 16(3): 420-5.
- [19]. Orlu, E.E., &Egbunike, G.N. (2009).Daily Sperm production of the Domestic fowl (*Gallus domesticus*) determined by quantitative Testicular histology and homogenate methods. *.Pakistan Journal of Biological Sciences*,12(20), 1359-1364
- [20]. Orlu,E.E.&Obulor,A.O(2014).Investigation on the effect of aqueous extract of *Acanthus montanus* on spermatogenesis in Swiss mice.*IOSRJournal of Pharmacy and Biological Sciences* ,9(3), 11-18

Adetutu Olubunmiobulor. " Evaluation of the Therapeutic Effect of Lycopene on Cypermethrin-Induced Reproductive Toxicity in Rats." *IOSR Journal of Environmental Science, Toxicology and Food Technology (IOSR-JESTFT)* 12.3 (2018): 10-16.